

Impact Factor:

ISRA (India) = 4.971
ISI (Dubai, UAE) = 0.829
GIF (Australia) = 0.564
JIF = 1.500

SIS (USA) = 0.912
PIHHI (Russia) = 0.126
ESJI (KZ) = 8.716
SJIF (Morocco) = 5.667

ICV (Poland) = 6.630
PIF (India) = 1.940
IBI (India) = 4.260
OAJI (USA) = 0.350

SOI: [1.1/TAS](#) DOI: [10.15863/TAS](#)

International Scientific Journal Theoretical & Applied Science

p-ISSN: 2308-4944 (print) e-ISSN: 2409-0085 (online)

Year: 2020 Issue: 01 Volume: 81

Published: 18.01.2020 <http://T-Science.org>

QR – Issue



QR – Article



Fazlitdin Khusniddinovich Olimkhuzhayev
Tashkent Dental Institute
Assistant Professor of the Department of Anatomy

Tohir Askarovich Askarov
Tashkent Pediatric Medical Institute
Doctor of Medical Sciences,
Professor, Head of the Department of General Surgery

Mirhalil Dzhililovich Akhmedov
Tashkent Pediatric Medical Institute
Assistant of the Department of General Surgery

Yokub Nishanovich Fayziev
Tashkent Pediatric Medical Institute
Candidate of Medical Sciences,
Associate Professor of the Department of General Surgery,

Ahmadjon Makhamadjonovich Ashurmetov
Tashkent Pediatric Medical Institute
Candidate of Medical Sciences,
Assistant of the Department of General Surgery,

Shoxsonam Abdullaevna Soliyeva
Tashkent Pediatric Medical Institute
3th year student direction medical business

LIVER MICRO-VESSEL FEATURES IN POSTNATAL ONTOGENESIS

Abstract: In an experiment on 226 white male outbred rats from birth to 8 months of age, different periods of postnatal ontogenesis were studied. We found that the initial link of blood outflow from the hepatic lobules are the initial hepatic venules, which are formed from the fusion of sinusoids in the subcapsular zone of the liver. From 2 weeks of age to the end of postnatal ontogenesis, liver revealed constantly occurring hepatic complexes. In postnatal ontogenesis, the main process is the formation of new structural and functional units in the subcapsular zone of the liver.

Key words: liver, ontogenesis, the lobule, the hepatic venules, sinusoidal vessels.

Language: English

Citation: Olimkhuzhayev, F. K., et al. (2020). Liver micro-vessel features in postnatal ontogenesis. *ISJ Theoretical & Applied Science*, 01 (81), 86-92.

Soi: <http://s-o-i.org/1.1/TAS-01-81-18> **Doi:**  <https://dx.doi.org/10.15863/TAS.2020.01.81.18>

Scopus ASCC: 2700.

Introduction

UDC 611.36:616.36- 089.87:577.95

According to modern concepts, the liver, occupying a special place between the external and

internal environment of the body, is involved in many metabolic processes.

Currently, a significant number of works have been accumulated devoted to the study of the

Impact Factor:

ISRA (India)	= 4.971	SIS (USA)	= 0.912	ICV (Poland)	= 6.630
ISI (Dubai, UAE)	= 0.829	PIHHI (Russia)	= 0.126	PIF (India)	= 1.940
GIF (Australia)	= 0.564	ESJI (KZ)	= 8.716	IBI (India)	= 4.260
JIF	= 1.500	SJIF (Morocco)	= 5.667	OAJI (USA)	= 0.350

formation of the structural foundations of the liver in humans and some mammals [1,2,3].

Based on the study of the ratio of intracellular and cellular restoration processes in internal organs, K.A. Zufarov (2000) notes that "the form of regeneration depends on the characteristics of the growth and development of the organ in ontogenesis."

Issues of postnatal formation of the liver have been the subject of many studies [4,5]. But in the vast majority of studies, the aim was to study parenchymal cells.

Despite numerous studies on organ regeneration, the problem of repairing a damaged liver remains relevant. Liver resection is a convenient and widespread model for studying organ regeneration in an experiment. It is used in surgical practice for injuries, echinococcosis and neoplasms of the liver [5,6,10]. In this regard, of great interest is the study of the morphology of the liver undergoing surgery and the identification of patterns of regeneration processes [7,8,9].

The purpose and objectives of the study

The aim of this study is to study the characteristics of the dynamics of changes in intraorgan vessels and the structural and functional unit of the liver - its segments in different periods of postnatal ontogenesis and to identify the dynamics of recovery processes after resection on the 15th day of postnatal development.

Material and research methods

The work was performed on 226 white mongrel rats males from birth to 30 months of age. All experimental animals were divided into 2 groups. In series I, postnatal ontogenesis was studied on 146 intact rats aged 1,3,5,7,10,12,14,21 days and 1, 3, 8,15,30 months after birth. The second group consisted of 80 animals that served as control. The timing of the study was chosen by us on the basis of the age periodization of laboratory animals (V.I. Zapadnyuk, 1971; R. Gossrau, 1975).

In the first series of experiments, pregnant females were selected and kept in vivarium conditions on an appropriate diet. After childbirth, they were separated separately with newborns and counted postnatal life of the rat pups.

To study the vascular architectonics of the liver, the methods of bichromic injection of intraorgan vessels with a mass of Herot in the modification of Kh.K. Kamilov (1970) and a mascara-gelatin mixture in a ratio of 1: 3 were used by F.N. Bakhadirov and F.Kh. Olimkhuzhayev (1995). Injection was performed through the thoracic aorta in the morning, and in young rats up to 1 month of age through the left ventricle of the heart. For the manufacture of enlightened preparations, pieces taken from the right lobe were performed according to the accelerated method of A.M. Malygin (1956). Serial sections 5-20 μ m thick were prepared from samples. On serial

sections, the cross-sectional area of the lobules, the detection depth and the diameter of the microvessels were measured. A three-dimensional reconstruction of the liver complexes was carried out. The area of the lobules was calculated by their true size at the level of detection of round lobular venules. Slices of the liver for histological studies were fixed in Carnoy fluid, FSU and 12% neutral formalin. Sections 3-5 μ m thick were stained with hematoxylin and eosin.

Morphometry was performed using an MOV-15X eyepiece micrometer using a P-2 binocular microscope. Liver mass was measured using an VT-500 analytical and torsion balance. The volume of the liver was determined using the device developed by us (rat. Proposal N1024 1991). Statistical processing of digital data was performed using tables to calculate the arithmetic mean and standard error and on the computer. Differences satisfying $P < 0.05$ were considered significant.

Study Results and Discussion

The results of our studies showed that in adult sexually mature rats the following types of lobules are constantly detected in the liver:

1) a lobule of type 1 — has a hexagonal shape, is bounded around by lobular (septal) vessels, and a central vein (hepatic vein of the first order) is located in its center;

2) type 2 lobule - formed from the confluence of 2-3 type 1 lobules, has a polygonal shape, 2-3 hepatic veins of the first order (central veins) are detected in the center, which are located at a certain distance from each other, there are sinusoids between them;

3) type 3 lobule - has a polygonal shape and, unlike type 2 lobules, its first-order hepatic veins (central veins) approach each other. As they deepen between them, sinusoidal vessels disappear, and they merge with the formation of a second order hepatic vein.

During the reconstruction of serial sections, in adult animals, along with lobules, constantly occurring liver complexes can be distinguished. They represent a higher than lobule level of structural organization of the hepatic parenchyma. Each such complex includes 2-3 neighboring slices, limited to several portal tracts.

In accordance with the structure of the lobules of each of the above types, the liver complex can be divided into 4 zones:

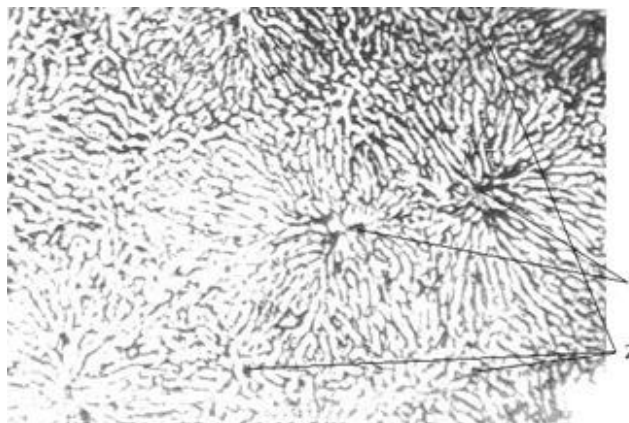
The zone I of the complex, located directly under the capsule of the organ, is characterized by the absence of a lobular structure characteristic of the liver. The vascular bed is represented by a sinusoidal network, among which are the initial hepatic venules. Each initial hepatic venule is formed from the fusion of several sinusoids. The internal lumen of the initial hepatic venules ranges from 14.7 to 25 microns. And their length is from 150 to 250 microns. The delivery vessels are represented here by terminal portal venules

Impact Factor:

ISRA (India) = 4.971	SIS (USA) = 0.912	ICV (Poland) = 6.630
ISI (Dubai, UAE) = 0.829	PIHHI (Russia) = 0.126	PIF (India) = 1.940
GIF (Australia) = 0.564	ESJI (KZ) = 8.716	IBI (India) = 4.260
JIF = 1.500	SJIF (Morocco) = 5.667	OAJI (USA) = 0.350

and arterioles. Interlobular and septal vessels do not reach the subcapsular zone and, therefore, lobular

organization of the liver microvessels is not detected in this zone.



Microphoto 1. Lobules of the liver. 14 days of postnatal development. Slices parallel to the fibrous (Glisson) capsule of the liver. Depth 180 microns from the fibrous capsule. Coloring: mascara gelatin (2% solution) bichromic injection. Lens x15, eyepiece x8. 1 - veins of the first dual (central vein), 2 - portal vessels.

Zone II begins at a depth of 30-90 microns from the surface of the liver and is represented by lobules of type I. The lobules are limited around the lobular and interlobular vessels and contain hepatic veins of the first order, formed from the confluence of the initial hepatic venules. The average cross-sectional area of the lobules ranges from 0.168 to 0.214 mm² (0.191 + 0.011 mm²).

Zone III is located at a depth of 210-270 μm from the surface of the liver, where adjacent adjacent lobules disappear between adjacent lobules and they join in pairs, forming lobules of type II containing 2 to 3 hepatic veins of the first order.

The IV zone is located at a depth of 320-360 μm from the fibrous capsule of the liver and represents the base of the liver complex. Lobules of type 3 are detected in this zone; its characteristic feature is the presence in the center of the lobules of merging 2-3 hepatic veins of the first order (central veins). From the fusion of the hepatic veins of the first order, hepatic veins of the second order are formed. The microvascular bed of the liver in postnatal ontogenesis in the early period is characterized by the absence of lobular organization of microvessels. Under the fibrous organ capsule is a single sinusoidal network.

Table 1. Indicators of hepatic complexes of liver in postnatal ontogenesis

Timing study blowing (days)	Level detected. around only veins (in microns)		Level disappeared - news related boundaries of lobules (in microns)		Level image. liver veins I of order (in microns)		Level image.liver. veins of the II order (in microns)	
	1 day	no		no		60	80	140
3 days	no		no		80	120	160	220
5 days	no		no		120	140	340	380
7 days	140	200	no		100	120	220	260
10 days	200	240	no		120	160	200	240
12 days	180	200	no		140	180	200	220
14 days	80	100	240	280	40	60	300	480
21 days	160	180	180	200	80	100	240	280
1MONTH	60	80	120	140	80	120	320	460
3MONTH	60	100	140	160	60	80	240	300
8MONTH	80	125	200	240	60	100	320	360
15MONTH	125	150	275	300	75	80	400	425
30MONTH	60	90	210	240	60	90	330	360

The initial link in the outflow of blood is not the central veins that are not detected in the subcapsular zone, but the initial hepatic venules, formed from the

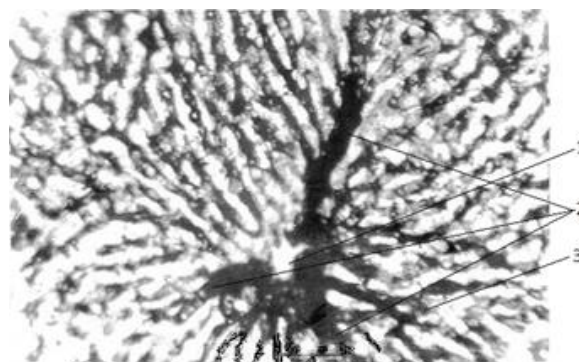
fusion of sinusoid vessels. It should be emphasized that the lobular organization of the microvasculature of the liver is not detected until 10 days, both in the

Impact Factor:

ISRA (India)	= 4.971	SIS (USA)	= 0.912	ICV (Poland)	= 6.630
ISI (Dubai, UAE)	= 0.829	PIHHI (Russia)	= 0.126	PIF (India)	= 1.940
GIF (Australia)	= 0.564	ESJI (KZ)	= 8.716	IBI (India)	= 4.260
JIF	= 1.500	SJIF (Morocco)	= 5.667	OAJI (USA)	= 0.350

subcapsular zone and in the deeper parts of the hepatic parenchyma. The terminal vessels branching into sinusoids in the subcapsular zone are terminal portal venules. In the deeper sections of the liver parenchyma, the blood supply is due to interlobular veins, which directly decompose into sinusoidal hemocapillaries. On the 10th day of life, at a depth of 240-260 microns, 3 segments of type 3 with a characteristic configuration appear. On the 12th day of life, the depth of zone I decreases by 1.5 times in

comparison with the previous period. At a depth of 160-180 μm , segments of type 2 appear, and segments of type 3 are found at a depth of 240-260 μm . On the 14th day of postnatal ontogenesis, type 1 lobules are found in the more surface layers of the liver at a depth of 40-80 microns. The second period of development of the microvasculature of the liver, which begins with a fortnight, is characterized by the continuous growth of lobules in the subcapsular region.



Microphoto 2. Lobules of the liver. 14 days of postnatal development. Slices parallel to the fibrous (Glisson) capsule of the liver. Depth 40 μm from the fibrous capsule.

Coloring: mascara gelatin (2% solution) bichromic injection. Lens x20, eyepiece x10. 1 - veins of the first dysfunction (central vein), 2 - initial hepatic venules, 3 - sinusoidal capillaries.

On day 21, at a depth of 80-100 μm , segments of $0.184 \pm 0.006 \text{ mm}^2$ are determined. On the 30th day of life, the average area of lobules is $0.175 \pm 0.004 \text{ mm}^2$. The completion of the second period is characterized by the formation of all links of the microvasculature of the liver, characteristic of adult animals.

In the third period, starting from 3 months of age, the structural and functional organization of the liver is stabilized and it acquires a structure characteristic of an adult organism.

Our studies have shown that the early postnatal period of mammalian life is characterized by the highest rates of development of the body and liver in particular. For 7 days after birth, the mass of rats increases 2 times, for 14 days - 4 times compared with that of newborns. Over 2 weeks of life, liver mass increases 3 times, over 8 months - 36 times compared with newborns.

When studying the area of lobules in a growing organism, a wave-like change in the average cross-sectional area of the lobules was found. When studying the microvasculature in postnatal ontogenesis, a wave-like change in the diameter and length of the liver microvessels was found. An

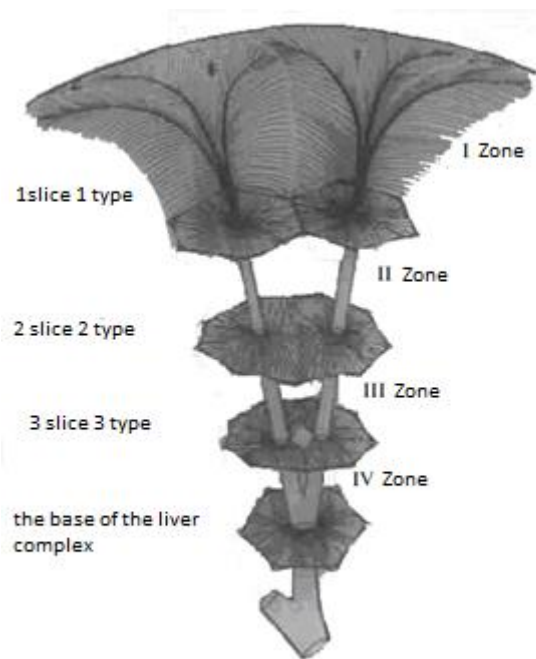
increase in all these indicators does not correspond to the multiplicity of growth of the mass of the liver. Given that the mass of the liver increases in the further stages of the study, fluctuations in the diameter and length of the microvasculature of the liver can be explained by the growth of the subcapsular zone and in all periods of the study, we probably dealt with newly formed vessels.

An analysis of our data showed that in all periods of postnatal ontogenesis, a zone consisting of a continuous sinusoidal network is determined under the fibrous capsule of the liver. Sinusoids often anastomose and their radial orientation is not pronounced. Sinusoidal vessels originate from the terminal portal venules.

In textbooks on anatomy and histology, as well as in most monographs devoted to normal and pathological liver morphology (A.S. Loginov, L.I. Aruin, 1985; V.V. Serov, K. Lapish, 1989; A. Sadridinov, 1993; E.A. Tursunov, 1994; L. Robert, 1986; IPMaly, 1987) the structural and functional unit of the liver is the classic hepatic lobule, with one central vein in the center. In our studies, 3 types of lobules were identified

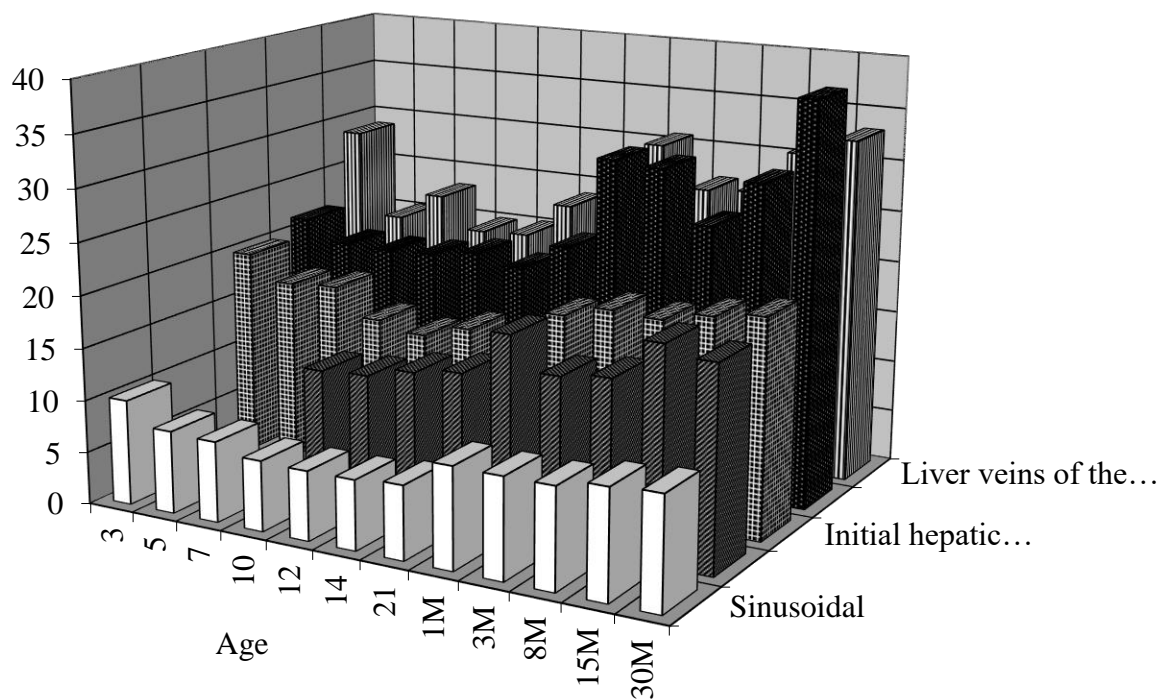
Impact Factor:

ISRA (India) = 4.971	SIS (USA) = 0.912	ICV (Poland) = 6.630
ISI (Dubai, UAE) = 0.829	PIHHI (Russia) = 0.126	PIF (India) = 1.940
GIF (Australia) = 0.564	ESJI (KZ) = 8.716	IBI (India) = 4.260
JIF = 1.500	SJIF (Morocco) = 5.667	OAJI (USA) = 0.350



1. Scheme of the liver complex. It is made on the basis of reconstruction of serial sections. On top is a fibrous capsule of the liver. Underneath is a sinusoidal capillary network. Then there are slices of 1, 2, 3 types.

Diagram 1. The diameter of the microvasculature of the liver in postnatal ontogenesis (in mkm)



Thus, we found that from two weeks to the end of postnatal ontogenesis, liver complexes are constantly found in the liver, which represent a higher

level of structural organization of the hepatic parenchyma than lobule.

Impact Factor:

ISRA (India)	= 4.971	SIS (USA)	= 0.912	ICV (Poland)	= 6.630
ISI (Dubai, UAE)	= 0.829	PIHHI (Russia)	= 0.126	PIF (India)	= 1.940
GIF (Australia)	= 0.564	ESJI (KZ)	= 8.716	IBI (India)	= 4.260
JIF	= 1.500	SJIF (Morocco)	= 5.667	OAJI (USA)	= 0.350

There are attempts in the literature to single out structures resembling complexes. E.V. Kapustina (1973) describes complexes in the cat's liver resembling rock crystal druse. However, it does not give the morphometric characteristics of the complex. The method of serial slices we used for the first time in parallel with the capsule of the liver made it possible to determine the morphometric parameters of the liver complexes and the lobules that form them, and to distinguish zones in the complex.

For the first time in all periods of postnatal ontogenesis, we have identified the initial hepatic venules. They are formed in the subcapsular zone from the fusion of several sinusoidal hemocapillaries of individual sectors of the sinusoidal network or within the lobules. Located topographically in the gap between sinusoid vessels and first order hepatic veins (central veins), they are the initial link in the outflow of blood in the hepatic microcirculation system. The initial hepatic venules are formed from the fusion of sinusoids from a certain sector of the lobule, are initially parallel to the capsule, and then go deep into the body. Similar vessels were discovered by A.M. Chernukh and N.Ya. Kovalenko (1976.), and later by N.Kh. Abdullaev and Kh.Ya. Karimov (1989) and were described as large and fairly regularly located, "arachnid liver venules" into which sinusoids flow at more or less even intervals.

The mass of the liver in the postnatal period of ontogenesis increases by 36 times. So, if at birth the weight of the liver is 0.236 ± 0.014 g, then after 8 months the mass of the liver is 8.495 ± 0.431 g. Knowing the multiplicity of the increase in the mass of the liver, we were entitled to expect multiple changes in the parameters of the microvasculature of the liver, as well as the cross-sectional area of the lobules, hepatic complexes heights. Studies have shown slight variations in the parameters of the investigated objects.

In postnatal ontogenesis, the diameter of the internal lumen of sinusoids significantly increases up to 21 days of postnatal ontogenesis and then it stabilizes. If we take into account that the liver mass increases in the further periods of the study, then the stabilization of the diameter of the sinusoids can be explained by the growth of the subcapsular zone and, apparently, in these periods of the study we were dealing with newly formed sinusoids. As for the length of the sinusoids, there is also a wave-like oscillation.

The diameter of the interlobular veins, around the lobular venules and hepatic veins of the first order also varies within small limits. Fluctuations in their diameter are accompanied by frequent increases and decreases in the depth of their detection.

Having examined the dynamics of changes in the average cross-sectional area of the lobules, we can conclude that it changes in a wave-like fashion. In all periods, we detected a fluctuation in the average cross-

sectional area of the lobules at the level of detection of the round lobular vessels. An increase in the indicator in the early stages (12 days) was replaced by a decrease (14 days). Then, the lobule area increased again (21 days). These fluctuations were expressed and the initial increase in area was replaced by a statistically significant decrease. The most logical explanation for such fluctuations, we consider the presence in the growing liver of the process of neoplasm of the lobules. In recent years, more and more information has appeared about the possibility of neoplasm of structural units not only in the liver, but also in other organs: in the small intestine A.Yu. Yuldashev (1988), in the lungs U. Mirsharapov (1992), in the kidneys of TR Ruziev (1993), in the spleen P.S. Kobilov (1994). Fluctuations in the mean cross-sectional area of the lobules is probably the result of a subcapsular neoplasm.

The height of the complex in postnatal ontogenesis undergoes significant changes. If the liver complexes are completely absent in the early periods of liver development (up to 7 days), then the appearance of the first functional structures (10 days) corresponds to the formation of the base of the liver complexes. These structures - lobules have a polygonal shape, with 2-3 hepatic veins of the first order in the center (3 type of lobules). Type 2 lobules are detected on day 12 and by day 14 lobules of type 1 are formed. But the process of formation of the liver complex is not limited to only these changes. The height of the complex in postnatal ontogenesis increases to 14 days, then begins to decrease (up to 21 days) and reaches its largest size by 1 month. The height of the liver complexes in these periods varies from 120 to 260 microns. The complexes detected at a later date are fully formed, and fluctuations in their height are insignificant. The height polymorphism of complexes remains until the end of the study.

Thus, the results of studies of the hemomicrocirculatory bed of a growing liver showed that postnatal formation can be divided into three periods:

1. From birth to 2 weeks of life. This period is characterized by the absence of lobular structure of the liver. The growth of microvessels is due to subcapsular growth.

2. From two weeks to three months. It differs from the previous period in the formation of the lobular structure of the liver. There is a structural and functional formation of various zones of the liver complex.

3. From three months to the end of life. This period is characterized by stabilization of the structural and functional organization of the microvasculature of the liver. Forming processes within the liver complexes are ending.

The study of the microvasculature of the liver in postnatal ontogenesis revealed a wave-like change in the average cross-sectional area of the lobules and the

Impact Factor:

ISRA (India)	= 4.971	SIS (USA)	= 0.912	ICV (Poland)	= 6.630
ISI (Dubai, UAE)	= 0.829	PIHHI (Russia)	= 0.126	PIF (India)	= 1.940
GIF (Australia)	= 0.564	ESJI (KZ)	= 8.716	IBI (India)	= 4.260
JIF	= 1.500	SJIF (Morocco)	= 5.667	OAJI (USA)	= 0.350

depth of the subcapsular zone. In the process of formation of the lobular structure in the growing organ, lobules first appear 3, then 2, and subsequently 1 types, which completes the formation of a new hepatic complex. An increase in the size of the microvessels of the liver complex is accompanied by a significant restructuring of its vascular architectonics.

Findings:

1. The initial link in the outflow of blood from the hepatic lobules is the initial hepatic venules, which are formed from the fusion of sinusoids in the subcapsular zone of the liver. From the merger of these venules, hepatic veins of the first order are formed (normal - the central veins).

2. From two weeks of age until the end of postnatal ontogenesis, in the liver, along with lobules, it is possible to distinguish constantly occurring liver complexes, which are higher than the lobule level of the structural organization of the hepatic parenchyma.

3. The early postnatal period (up to 10 days) of the development of rat liver is characterized by:

- the absence of lobular structure both in the subcapsular zone and in the underlying departments of the hepatic parenchyma; - the presence of initial hepatic venules formed in the subcapsular zone from the fusion of several sinusoids. These venules are the initial link in the outflow of blood in the system of hepatic microcirculation;

- enhanced liver growth mainly due to subcapsular growth.

4. Changes in the parameters of the microvasculature of the liver lobules as well as the height of the liver complexes and the cross-sectional area of the lobules in postnatal ontogenesis are far behind the multiplicity of the increase in liver mass.

5. The processes of formation of microvascular organ architectonics in postnatal ontogenesis have common features. The main process is the formation of new structural and functional units in the subcapsular zone of the liver.

References:

1. Bahadyrov, F.N., Alimkhodzhaev, F.Kh., & Sheverdin, V.A. (2005). *Microcirculatory bed of a growing and regenerating liver* // In the book: Results of scientific research on medical science and healthcare. Sat scientific tr. (pp.60-63). Tashkent.
2. Zufarov, K.A., Sadridinov, A.F., & Knyazeva, L.S. (1993). *Histophysiology of the liver and intrahepatic biliary tract*. The text of the lecture. / First Tash. state honey. inst. (p.26). Tashkent.
3. Weight, M. G. (1985). *Human anatomy*. (p.458). Moscow: Medicine.
4. Sarkisov, D.S. (2005). *Structural foundations of adaptation and compensation of impaired functions*. - In the book: Actual issues of medical science and healthcare. Vol. XXXII. Sat scientific tr. (pp.41-45). Moscow.
5. Solopaev, B.P. (2007). *The problem of regeneration of pathologically changed organs and the reversibility of pathological changes, regeneration therapy is a reserve of the struggle for human health*. Regeneration, adaptation, homeostasis. (pp.8-15). Gorky.
6. (1991). *Surgical treatment of cirrhosis using regeneration stimulants* / B.A. Akhundjanov, V.A. Alimov, I.P. Kim, A.A. Abdurakhmanov. – (p.110). Tashkent: Publishing House. Ibn Sina.
7. (2018). Dynamic morphological changes in the experimental model of liver contusion in small laboratory animals. // A.M.Khadjibaev, P.K.Sultanov – *The bulletin of emergency medicine Vol.11 2'2018*, pp. 48 – 56.
8. Ekataksin Wichai, Wake Kenjiro (2007). Liver units in three di-mensions. 1 Organization of argyrophilic connective tissue skeleton in porcine liver with particular reference to the "compound hepatic lobule" // *Amer.J. Anat.* - 2007. - Vol. 201, N 2, pp.113-115.
9. Fausto, N., Laird, A.D., & Webber, E.M. (2009). Role of growth factors and cytokines in hepatic regeneration (Serial review) // *FASEB J. 2009.* - Vol. 9, N 15, pp.1527 - 1536.
10. Kimura Fumio, Miyasaki Masaru, Suwa Toshikazu (2008). Increased Levels of Human Hepatocyte Growth Factor in Serum and Peritoneal Fluid After Partial Hepatectomy // *American J. of Gastroenterology. 2008.* - Vol. 26, N 12, pp.133 - 137.